

# Rounds

Animal Health  
Department

Medical Rounds

*"medicine for all"*



*Caring for Stranded Marine Animals*

NATIONAL  
MARINE  
L I F E  
CENTER

# Notes

Veterinary Research  
Department

Under the microscope

[rwilliams@nmic.org](mailto:rwilliams@nmic.org)

Rounds Notes is a report on the health of animals at the National Marine Life Center from Sea Rogers Williams VMD for the staff, volunteers, and community of the center including professionals involved the captive care of similar species, the views expressed are not necessarily that of NMLC. Information in Rounds Notes should be considered confidential and used solely to benefit the health of aquatic animals everywhere.

Jan 16, 2013

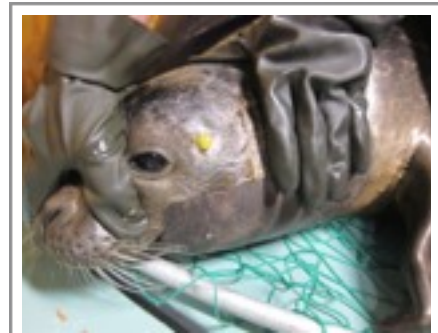*Rounds Notes*

**3: 10-11 (2013)**

## HeadHeadlines News:

### **Towennnd's infection still active**

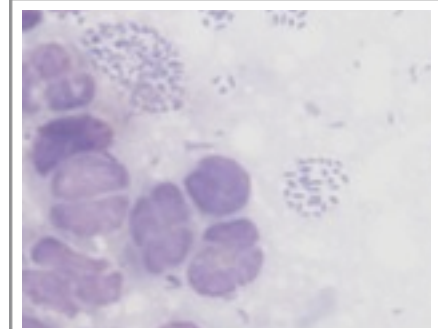
Cytology stills shows active inflammation and infection in the left ear, the question is, will Townsend respond to medication after surgery, when many seals without surgery have failed to respond. We instilled a medicated wax (an anhydrous lanolin) with ketoconazole, enrofloxacin, and betamethasone, and we'll see if this does the trick.



## Clinical Update: Ear cytology

### **we put the "itis" in otitis**

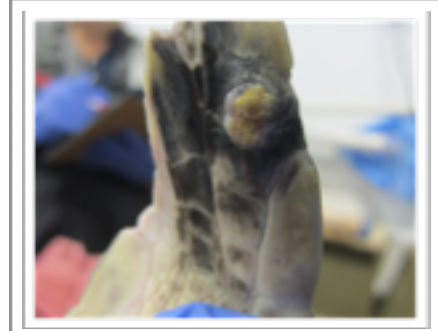You can see the neutrophils with intracellular bacteria and colonies of extra cellular bacteria in the ear cytology taken from Townsend after the last scan, no doubt that an active infection is still taking place



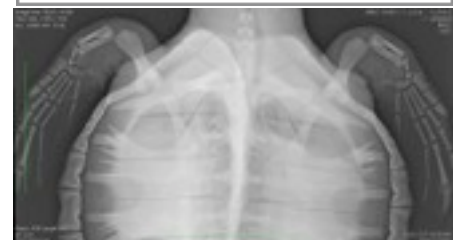## Sea Turtles:Gerald #21

### **rads today**

This is a block of text to act as a place holder This is a block of text to act as a place holder This is a block of text to act as a place holder This is a block of text to act as a place holder This is a block of text to act as a place holder place holder This is a block of text to act as a place holder This is a block of text to act as a place holder



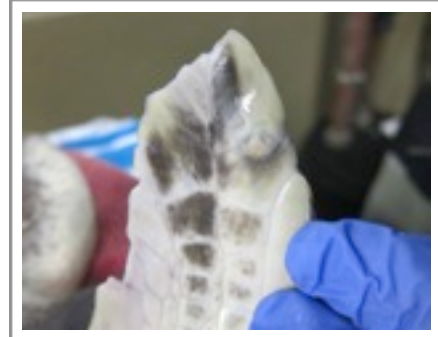
Rads showed minor osteolysis with R & L D3 P 3-4 with mild soft tissue swelling, lesions are typical and expected to heal with supportive care and topical treatment .



## Sea Turtles: Caroline 24

### flipper tips

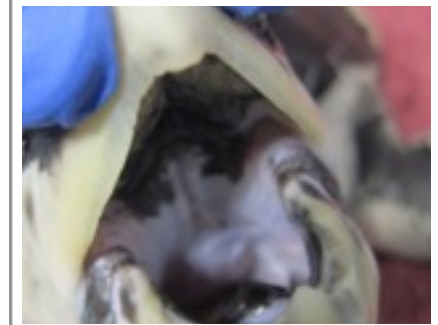Minor flipper tip lesions RFF>LFF were observed, overall Caroline appears to be doing well  
weight 3.27 SCL=26.7, SCW =24.3  
Albumin is improved and normal, ALKP, CK, LDH, chol., and uric acid all elevated but improved. She in is the rad rotation and bloods again in another 2 mos.



## Sea Turtles: Topsy 20

### by word of mouth

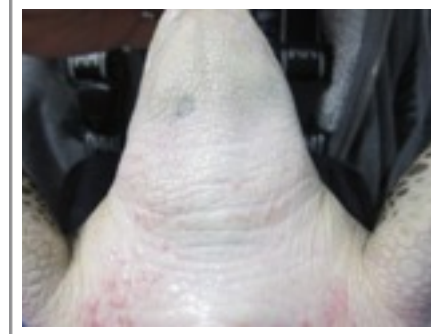
Topsy is doing well, but has some small pin-point lesions in the back of the oral cavity, we'll keep an eye on it.  
wt=2.352 kg, SCL=22.9, SCW=21.5 cm  
HR= 56, strong Doppler signal, other PE WNL



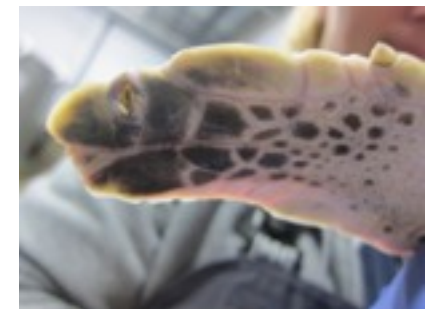## Sea Turtles: Besty 22

### don't be rash

Clinically Betsy is doing well, but she has a ventral rash and circular skin lesion on the neck, and mild flipper tip lesions  
wt=3.45kg HR=48  
Blood work showed normalized Glu, Ca. and K, and decreased (improved) but slightly elevated LDH, Chol., and a persistent uric acid of 0.5. CWCT

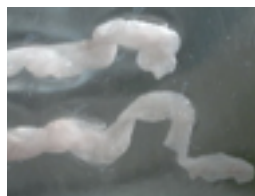

Phenix, Popi, and Walter also received physical exams today and are doing fine, and of course Hotlips is back in her element.



## Under the Microscope: Finback

A parasite sample from Riverhead Foundation from a Fin Back Whale was evaluated, while the ID is tentative it appears to be another case of Crassicaudosis.



*C Rogers Williams VMD*

Sea Rogers Williams VMD  
attending veterinarian and director of science

