

Rounds Notes is a report on the health of animals at the National Marine Life Center from Sea Rogers Williams VMD for the staff, volunteers, and community of the center including professionals involved the captive care of similar species, the views expressed are not necessarily that of NMLC. Information in Rounds Notes should be considered confidential and used solely to benefit the health of aquatic animals everywhere.

Feb 6, 2013

Rounds Notes

5: 16-18 (2013)

HeadHeadlines News: Townsend

by-line

Townsend weighed in at 40.7kg, BS 6/10, TPR 99.4, 60, 20 no d/c from the left ear, but swab collected, incision has long healed, other PE WNL

Cytology: chronic active inflammation with degenerate neutrophils, monocytes and rafts of bacteria.

The forth (of 4) left ear infusions with BNT, was given, after this treatment we will convene a status reviews next week



Clinical Update: Pickel

by-line

New radiographs were taken of Pickle and DV views of our cooters to compare bone density. Pickle is anorexic, lethargic, and has a soft shell. Blood gas and ionized calcium were reasonable, we are tube feeding and going to add a calcium supplement and our standard husbandry package. This cooter may have suffered an out-of-habitat and hypothermic event before coming to the NMLC for advanced care.



Sea Turtles: Topsy 20

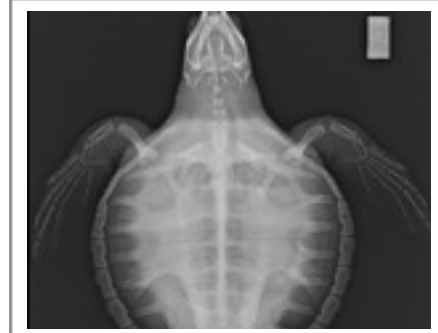by-line

CC: resolving oral lesions

Last Blood: 11-29-12, increased ALKP and LDH, WBC (12.5) 3/6/13

Last Rads: 2-6-13

wt=2.53kg, SCL =24.0, SCW=22.2, depth 10.0 cm HR=48
 small abrasion on head, treated with SSD.



Sea Turtles: Gerald 21

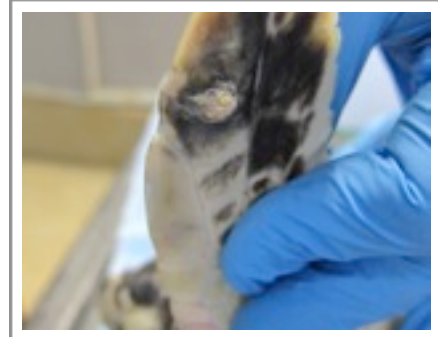
by-line

CC: flipper tip lesions

Last Blood: 1-10-13, increased ALKP, monitor UA, LDH

Last Rads: 1-16-13 repeat flipper tips

wt= 4.65 kg, HR=52, front flipper tips are still active L>R, R is almost healed



Sea Turtles: Betsy 22

by-line

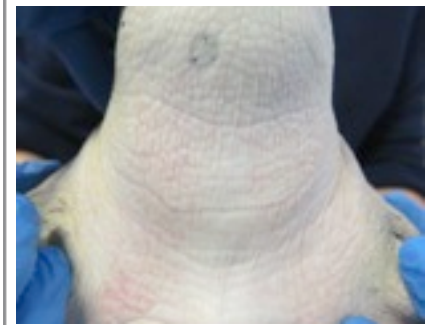CC: rash and circular neck lesion, flipper tip lesions

Last Blood: 1-10-13, improving

Last Rads: 1-23-13, repeat flipper tips

wt=3.81 kg HR=52

mild active front flipper tip lesions, and unchanged circular neck lesion, may be an old "bite" wound



Sea Turtles: 'wild' Walter 23

by-line

CC: inflammatory response

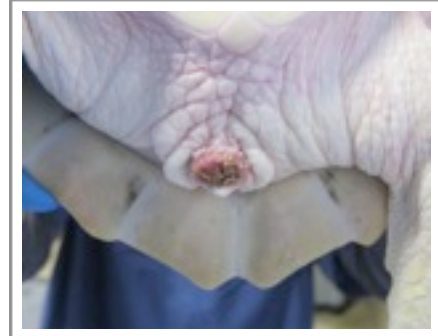
Meds: doxy 50mg PO SID itra 20mg PO SID 30d

Last Blood: 1-30-13, increased WBC (14), LDH, GLOB, 2-6-13

Last Rads: 1-31-13 WNL (needs horz lat)

wt= 4.6 kg SCL=31.1, SCW=29.1 HR=48

PE WNL, hold on meds, repeat CBC today and decide.



Sea Turtles: Carolyn 24

by-line

CC: flipper tip lesions

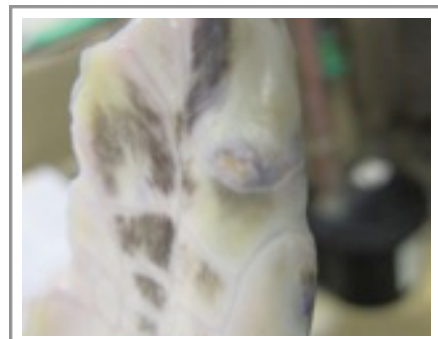
Last Blood: 1-10-13, improving

Last Rads: Due

wt= 3.55kg SCL = 28.0, SCW=25.3, HR= 48

R front flipper tip lesion, L has healed

Adm 0.28cc fortaz IM P: blood and assess abx therapy



Sea Turtles: Phoenix 25**by-line**

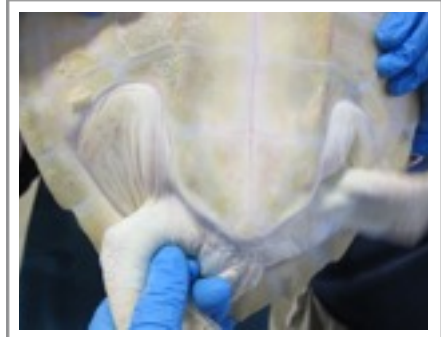CC: resolved left peri-ocular minor trauma

Last Blood: 11-29-12 CBC, CP; BG 12-12-12, stable- 2-6-13

Last Rads: Due

wt=4.4 kg SCL=30.5, SCW=28.2, HR=48

Right inguinal rash P: CBC/CP, also report of bite to LFF, no visible wound or lesion.

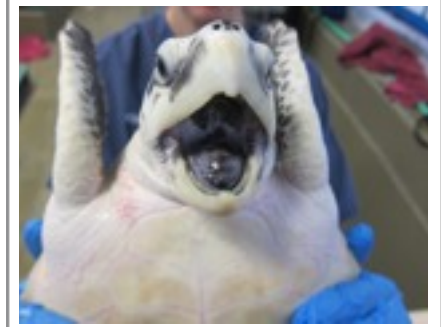**Sea Turtles: Ernest 26****by-line**

CC: active flipper tip lesions

Last Blood: 1-10-13, improving

Last Rads: 1-9-13, phlange autolysis

wt= 2.50 kg, HR=44, mild but active flipper tip lesions and slight rash R axilla

**Sea Turtles: Papi 27****by-line**

CC: bruising to right lower rhampotheca

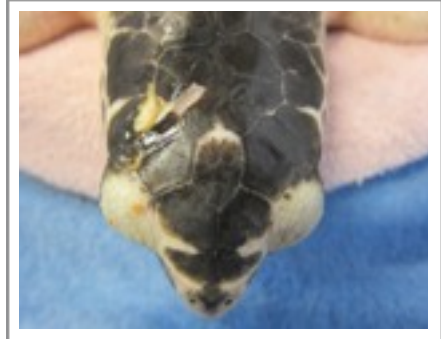Last Blood: 11-29-12, BG 12-2-12, stable

Last Rads: Due

wt= 3.27kg, SCL=26.9, SCW=24.5

bite wound to head, abrasion and ulceration, applied SSD, apply SSD SID, minor R FF tip lesion

Adm: fortaz 0.26 IM



Sea Rogers Williams VMD
attending veterinarian and director of science



ISTAFF: Kathv Zaezebski. Bridget Dunnigan. Kate Shaffer. Adele Raphael. Sarah Trudell